



12-2024

Houge-Janssens Syndrome-1 Associated with Protein Phosphatase 2 Regulatory Subunit B' Delta and Epilepsy: A Case Report

Dua Saleem

Aga Khan University, Hospital, Karachi

Fizza Akbar

Aga Khan University Hospital Karachi

Noor Zeeshan

Aga Khan University Hospital, Karachi

Rabab Jafry

Aga Khan University Hospital, Karachi

Salman Kirmani

Aga Khan University Hospital, Karachi

See next page for additional authors

Follow this and additional works at: <https://ecommons.aku.edu/pjns>



Part of the [Neurology Commons](#)

Recommended Citation

Saleem, Dua; Akbar, Fizza; Zeeshan, Noor; Jafry, Rabab; Kirmani, Salman; and Jafri, Sidra Kaleem (2024) "Houge-Janssens Syndrome-1 Associated with Protein Phosphatase 2 Regulatory Subunit B' Delta and Epilepsy: A Case Report," *Pakistan Journal of Neurological Sciences (PJNS)*: Vol. 19: Iss. 3, Article 10. Available at: <https://ecommons.aku.edu/pjns/vol19/iss3/10>

Houge-Janssens Syndrome-1 Associated with Protein Phosphatase 2 Regulatory Subunit B' Delta and Epilepsy: A Case Report

Authors

Dua Saleem, Fizza Akbar, Noor Zeeshan, Rabab Jafry, Salman Kirmani, and Sidra Kaleem Jafri

HOUGE-JANSSENS SYNDROME-1 ASSOCIATED WITH PROTEIN PHOSPHATASE 2 REGULATORY SUBUNIT B' DELTA AND EPILEPSY: A CASE REPORT

Dua Saleem¹, Fizza Akbar¹, Noor Zeeshan², Rabab Jafry², Salman Kirmani¹, Sidra Kaleem Jafri¹

¹Aga Khan University Hospital, Karachi

Corresponding Author: Sidra Kaleem Jafri Aga Khan University Hospital, Karachi **Email:** sidrakaleemjafri@gmail.com

Date of submission: March 29, 2024 **Date of revision:** October 23, 2024 **Date of acceptance:** November 18, 2024

ABSTRACT

Houge-Janssens syndrome 1 is a rare autosomal dominant disorder with approximately 100 case reports worldwide. Here, we present a case of a Pakistani toddler who presented with epilepsy and developmental delay. Family history was significant with reported and documented developmental delays in both father and elder sister, with subsequent improvement. Trio-whole-genome sequencing (WGS) and Sanger sequencing were performed, revealing a heterozygous LP variant NM_006245.4: c.626A>C, p.(His209Pro) in the girl. The same variant was also identified in her father and sister. This case sheds light on the variability of phenotypic expression amongst affected individuals and recommends the need for further genotype-phenotype correlation and studies.

Keywords

PPP2R5D, Intellectual developmental disorder, Epilepsy

INTRODUCTION

Houge-Janssens syndrome 1 (HJS1) (Gene MIM# 601646, Phenotype MIM# 616355), also known as Protein Phosphatase 2 Regulatory Subunit B' Delta (PPP2R5D)-related intellectual development disorder (IDD), Mental Retardation, Autosomal Dominant 35 (MRD35), is a rare genetic condition that occurs due to the pathogenic (P)/likely pathogenic (LP) variants in PPP2R5D. Around 100 cases have been reported in the literature.¹

This disorder may present with facial dysmorphism (macrocephaly, broad forehead, hypertelorism, tented lip, open mouth), global developmental delay, intellectual disability, hypotonia, absent speech, autism, hydrocephalus, and possibly epilepsy, along with potential ophthalmologic, endocrine, skeletal, genital, and cardiac issues.²⁻⁴

PPP2R5D is located on chromosome 6p21.1 and encodes the regulatory subunit family B56, of the heteromeric enzyme protein phosphatase 2A. (PP2A)⁵ The PP2A proteins are responsible for the phosphorylation of Serine and Threonine. PPP2R5D is expressed in the brain, eye, and heart and plays a vital role in learning and memory.⁵ PP2A, a heterodimeric core enzyme, forms a holoenzyme with PPP2R5D, which plays a role in the PI3K/AKT signaling pathway. This pathway is involved in neuronal function. In addition, PP2A is involved in cell growth mediated by glycogen synthase kinase 3 beta and regulation of gene transcription. The Lissencephaly gene (L1S1) pathway, which is involved in neuronal migration and development, is related to the PPP2R5D gene.⁶

In this case report, we present a toddler with a clinical diagnosis of global developmental delay having paternally inherited PPP2R5D-related intellectual developmental disorder type 35 (ADID35) from Pakistan.

CASE PRESENTATION

The patient, a full-term infant born via elective C-section to non-consanguineous parents, presented to Aga Khan University Hospital at seven months with status epilepticus, including generalized tonic-clonic seizures associated with fever, decreased activity, and poor oral intake. There was a significant developmental delay, with only partial neck holding at seven months and unable to engage in basic motor and social behaviors. On examination, she had mild facial dysmorphism, hypotonia, and brisk reflexes. Her family history revealed language and learning issues in the father and motor delays in an elder sibling diagnosed with spastic diplegic cerebral palsy.

At nine months, the patient experienced another episode of status epilepticus, prompting multiple hospitalizations for breakthrough seizures. Laboratory investigations, including blood work, cerebrospinal fluid analysis, and CT scans, were normal, while EEG at seven and nine months showed abnormal focal seizure patterns and hemispheric dysfunction (Figure 1). MRI findings (Figure 2) revealed T2/FLAIR hyperintensities in periventricular white matter, irregular ventricles, and thinning of the corpus callosum.

DISCUSSION

PPP2R5D-related neurodevelopmental disorders have a narrow mutational spectrum as only 17 P/LP variants have been identified to date in literature.¹ The variant in this case was classified as LP based on the American College of Medical Genetics and Genomics (ACMG) criteria, and the following scoring criteria were met, explaining the variant classification.⁷

PM1: Located in a mutational hot spot and/or critical and well-established functional domain (e.g. active site of an enzyme) without benign variation.

PM2: Absent from population database (gnomAD)

PP2: Missense variant in a gene that has a low rate of benign missense variation and in which missense variants are a common mechanism of disease.

PP3: Multiple lines of computational evidence support a deleterious effect on the gene or gene product (conservation, evolutionary, splicing impact, etc.).

The Clinvar database reported a total of 41 P/LP variants.⁸ We add to this literature by presenting a patient with a heterozygous LP variant NM_006245.4:c.626A>C, p.(His209Pro). Dysmorphic facial features including frontal bossing, hypertelorism, and long face have also been reported as common features of PPP2R5D-related intellectual disability (ID) in various studies.⁹⁻¹¹ Some studies also report narrow foreheads, down-slanted palpebral fissures, hypotonic facies, tented lips, dolichocephaly, and plagiocephaly as prominent findings, however, all these findings were absent from our patient. Houge et al. in a study of 1133 patients identified four patients with ADID35 that reported macrocephaly, ventriculomegaly, and hydrocephalus as pertinent findings.¹¹ Several other researchers have also described increased head circumference as a prominent feature of ADID35. A study also reports a rare case of microcephaly, whereas our patient demonstrated a normal head circumference

with no signs of ventriculomegaly or hydrocephalus.¹² Global developmental delay (GDD) and Intellectual disability (ID) affect 1% to 3% of the population worldwide and numerous studies have demonstrated GDD and ID both to be one of the major findings in ADID35.^{13,14} Consistent with prior research findings, our patient also demonstrated GDD such that she achieved only partial neck holding at seven months and had globally delayed milestones. The presence of autism spectrum disorder (ASD) in PPP2R5D-related ID has also been reported in various studies. However, given the young age of our patient, further follow-up over a long period would be necessary to investigate the development of ASD. A study conducted by Houge et al. described persistent hypotonia as a similar finding in seven patients diagnosed with ADID35.¹¹ Our patient confers on this finding as she had generalized hypotonia accompanied by brisk reflexes. Over the years, neuroimaging has been used as a screening and diagnostic tool in patients with global developmental delays and neurodevelopmental disorders.

Various studies have revealed brain abnormalities such as ventriculomegaly, dysmorphic corpus callosum, white matter abnormalities, cavum septum, and arachnoid cysts to be associated with PPP2R5D-related ID.^{6,9,10,15} Similarly, upon neuroimaging, white matter abnormalities and thinning of the corpus callosum were discovered in our patient. Grey matter heterotopia has been associated with neurodevelopmental delay and epilepsy.¹⁶ A report by Alhajaj et al also describes a patient with PPP2R5D mutation with epilepsy and neurodevelopmental delay with the presence of grey matter heterotopia, and our patient also confers to this finding.¹⁷ Epilepsy has been reported in almost half of the patients.^{5,8,13}

Our patient adds to this literature as she demonstrated epileptic encephalopathy with generalized tonic-clonic seizures, and right-sided focal seizures with the need for regular antiseizure medication. This is also

consistent with a study by Madaan et al. that also reported epileptic encephalopathy.¹⁸

Other clinical signs and/or defects have also been reported including genital defects (hypospadias), cardiac defects (VSD, ASD, etc.), ophthalmological defects (myopia, strabismus, etc.), endocrine defects, and skeletal defects (scoliosis, hip dysplasia, etc.).^{6,9,10,15} On the contrary, we did not discover any of the defects in our patient. Most studies have shown de novo P/LP variants to be the cause of PPP2R5D-related ID with a negative family history. N. Oyama et al. presented their work on 76 patients harboring PPP2R5D variants, with 68 harboring de novo P/LP variants, and four siblings with dominantly (maternally) inherited P/LP variant which is the only previous work mentioning a dominantly inherited variant. This maternally inherited variant is a missense variant (Glu197Gly) The mother was said to be mildly effected, however details were not mentioned.¹ Interestingly, the work of N. Oyama et al. stratified the P/PL variants in three functional groups, (1) variants with exclusively reduced C-binding activity, (2) variants with exclusively reduced liprin- α 1 binding activity, and (3) variants demonstrating reduction in both C-binding and liprin- α 1 binding activity. The functional impact of the variants was correlated to phenotypical severity. Variant Glu197Gly showed a retained A/C binding but reduced

liprin- α 1 binding which is likely to explain decreased clinical severity in the inherited case. Thus, the impact of different variants in PPP2R5D subsequently affect B56 δ function in brain and other tissues is hypothesized to lead to different disease severities which needs to be further elucidated in animal and cell models.

This case is the second report of an inherited PPP2R5D variant with a positive family history, showing improvements in the father and sister. The variable expressivity remains unclear, and genetic testing is crucial for differentiating PPP2R5D-related ID from other causes of developmental delay.^{13,15,19} Clinical exome sequencing facilitates early diagnosis and timely interventions. A multidisciplinary approach involving pediatricians, geneticists, neurologists, and therapists is critical for optimal management and improved outcomes.

CONCLUSION

We report the first case in Pakistan of PPP2R5D-related ID, caused by a paternally inherited heterozygous variant. This case highlights genotype-phenotype variability and emphasizes the importance of early diagnosis and targeted management in rare genetic disorders.

REFERENCES

1. Oyama N, Vaneynde P, Reynhout S, Pao EM, Timms A, Fan X, et al. Clinical, neuroimaging and molecular characteristics of PPP2R5D-related neurodevelopmental disorders: an expanded series with functional characterisation and genotype–phenotype analysis. *J Med Gen.* 2023;60(5):511-22.
2. Biswas D, Cary W, Nolte JA. PPP2R5D-related intellectual disability and neurodevelopmental delay: a review of the current understanding of the genetics and biochemical basis of the disorder. *Int J Mol Sci.* 2020;21(4):1286.
3. Yan L, Shen R, Cao Z, Han C, Zhang Y, Liu Y, et al. A novel missense variant in the gene PPP2R5D causes a rare neurodevelopmental disorder with increased phenotype. *BioMed Res Int.* 2021;2021.
4. Madaan P, Kaur A, Saini L, Paria P, Vyas S, Sharma AR, et al. PPP2R5D-Related neurodevelopmental disorder or developmental and epileptic encephalopathy?: a novel phenotypic description and review of published cases. *Neuropediatrics.* 2021;53(01):020-5.
5. Jong CJ, Merrill RA, Wilkerson EM, Herring LE, Graves LM, Strack S. Reduction of protein phosphatase 2A (PP2A) complexity reveals cellular functions and dephosphorylation motifs of the PP2A/B δ holoenzyme. *J Biol Chem.* 2020;295(17):5654-68.
6. Shang L, Henderson LB, Cho MT, Petrey DS, Fong CT, Haude KM, et al. De novo missense variants in PPP2R5D are associated with intellectual disability, macrocephaly, hypotonia, and autism. *Neurogenetics.* 2016;17(1):43-9.
7. Richards S, Aziz N, Bale S, Bick D, Das S, Gastier-Foster J, et al. Standards and guidelines for the interpretation of sequence variants: a joint consensus recommendation of the American College of Medical Genetics and Genomics and the Association for Molecular Pathology. *Genet Med.* 2015;17(5):405-24.
8. List of variants in gene PPP2R5D reported by New York Genome Center University of Utah: ClinVar Miner; 2023 [Available from: <https://clinvarminer.genetics.utah.edu/variants-by-gene/PPP2R5D>. Accessed on July 6, 2024
9. Biswas D, Cary W, Nolte JA. PPP2R5D-Related Intellectual Disability and Neurodevelopmental Delay: A Review of the Current Understanding of the Genetics and Biochemical Basis of the Disorder. *Int J Mol Sci.* 2020;21(4).
10. Yan L, Shen R, Cao Z, Han C, Zhang Y, Liu Y, et al. A Novel Missense Variant in the Gene PPP2R5D Causes a Rare Neurodevelopmental Disorder with Increased Phenotype. *Biomed Res Int.* 2021;2021:6661860.
11. Houge G, Haesen D, Vissers LE, Mehta S, Parker MJ, Wright M, et al. B56 δ -related protein phosphatase 2A dysfunction identified in patients with intellectual disability. *J Clin Invest.* 2015;125(8):3051-62.
12. Verbinnen I, Vaneynde P, Reynhout S, Lenaerts L, Derua R, Houge G, et al. Protein Phosphatase 2A (PP2A) mutations in brain function, development, and neurologic disease. *Biochem Soc Trans.* 2021;49(4):1567-88.
13. Moeschler JB, Shevell M. Comprehensive evaluation of the child with intellectual disability or global developmental delays. *Pediatrics.* 2014;134(3):e903-18.
14. Mithyantha R, Kneen R, McCann E, Gladstone M. Current evidence-based recommendations on investigating children with global developmental

- delay. Arch Dis Child. 2017;102(11):1071-6.
15. Stojanovic JR, Miletic A, Peterlin B, Maver A, Mijovic M, Borlja N, et al. Diagnostic and Clinical Utility of Clinical Exome Sequencing in Children With Moderate and Severe Global Developmental Delay / Intellectual Disability. J Child Neurol. 2020;35(2):116-31.
 16. Di Nora A, Costanza G, Pizzo F, Oliva C, Di Mari A, Greco F, et al. Gray matter heterotopia: clinical and neuroimaging report on 22 children. Acta Neurologica Belgica. 2022;122(1):153-62.
 17. Alhajaj G, Lacroix C, Trakadis Y, Garfinkle J, Srour M. An in-frame deletion affecting the critical acid loop of PPP2R5D is associated with a neonatal lethal form of PPP2R5D-related neurodevelopmental disorder. Am J Med Gen Part A. 2023.
 18. Madaan P, Kaur A, Saini L, Paria P, Vyas S, Sharma AR, et al. PPP2R5D-Related Neurodevelopmental Disorder or Developmental and Epileptic Encephalopathy?: A Novel Phenotypic Description and Review of Published Cases. Neuropediatrics. 2022;53(1):20-5.
 19. Ropers HH. Genetics of early onset cognitive impairment. Annu Rev Genomics Hum Genet. 2010;11:161-87.

Conflict of interest: Author declares no conflict of interest.

Funding disclosure: Nil

Authors' contribution:

Dua Saleem; concept, case management, manuscript writing

Fizza Akbar; case management, manuscript writing

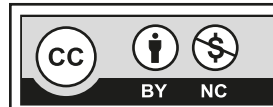
Noor Zeeshan; case management, manuscript writing

Rabab Jafry; case management, manuscript writing

Salman Kirmani; case management, manuscript writing

Sidra Kaleem Jafri; concept, case management, manuscript revision

All the authors have approved the final version of the article and agree to be accountable for all aspects of the work.



This is an Open Access article distributed under the terms of the Creative Commons Attribution-Non Commercial 2.0 Generic License.