



6-2024

Recurrent Intraosseous Myxoma: A Case Report

Alma Corazon T de la Cruz

The Medical City, Ortigas Avenue, Pasig City, Philippines

Michael N Sabalza

Quirino Memorial Medical Center, Project 4, Quezon City, Philippines

Follow this and additional works at: <https://ecommons.aku.edu/pjns>



Part of the [Neurology Commons](#)

Recommended Citation

Cruz, Alma Corazon T de la and Sabalza, Michael N (2024) "Recurrent Intraosseous Myxoma: A Case Report," *Pakistan Journal of Neurological Sciences (PJNS)*: Vol. 19: Iss. 2, Article 6.

Available at: <https://ecommons.aku.edu/pjns/vol19/iss2/6>

RECURRENT INTRAOSSEOUS MYXOMA: A CASE REPORT

Alma Corazon T de la Cruz¹, Michael N Sabalza^{1,2}

¹The Medical City, Ortigas Avenue, Pasig City, Philippines

²Quirino Memorial Medical Center, Project 4, Quezon City, Philippines

Corresponding Author: Alma Corazon T de la Cruz A The Medical City, Ortigas Avenue, Pasig City, Philippines **Email:** acpotdlt@gmail.com

Date of submission: April 2, 2024 **Date of revision:** June 13, 2024 **Date of acceptance:** June 25, 2024

ABSTRACT

Myxomas are rare, benign but locally aggressive neoplasms that are of mesenchymal origin. These tumors are usually diagnosed only when they have grown enough to cause symptoms because of their indolent nature, hence imaging plays a large role in the diagnosis of these tumors. Imaging findings may include well-circumscribed multinodular masses with destruction of adjacent bony structures. Treatment of these tumors is complete resection and close follow up. Early recognition with physical examination and imaging studies, close follow up and multidisciplinary treatment are needed to achieve the best results for patients. We present a 34-year-old male who presented with proptosis and diplopia as part of a recurrent intraosseous myxoma three months after craniotomy for tumor excision.

KEYWORDS: Calvarial, Intraosseous, Myxoma

INTRODUCTION

Myxomas are rare, benign, yet locally aggressive neoplasms that are of mesenchymal origin.¹ These tumors are more commonly found in soft tissues, particularly the heart. Occasionally, these tumors can be seen in bones, with a predilection for the mandibles.² While there have been several case reports and review articles characterizing intracranial myxomas, most of these lesions are in the skull base (e.g. middle fossa, parasellar area, jugular regions)^{1,3-5} and sinuses. There is a very limited number of articles describing calvarial intraosseous myxomas, their presentation, characteristics, and behavior. It is important to include these tumors in differential diagnoses when dealing with intraosseous neoplasms. Knowing how to treat these lesions is important, but equally important is how to know how to follow them up to detect recurrence early and prevent disfiguring changes in the patient.

CASE PRESENTATION

We present a 34-year-old male who was initially seen because of a bulge over the left eye accompanied by

redness, proptosis of the eye and doubling of vision. This bulge was treated as a tumor, and he underwent a craniotomy for tumor resection. Histopathology was read as a benign bone tumor consistent with myxoma of the bone with no significant mitotic activity. Immunohistochemistry for CD68, S100, and CD1a ruled out Langerhan's cell histiocytosis. No further treatment was advised.

The patient followed-up with the primary surgeon at three months post-surgery because he again noted that his left eye was mildly bulging out and he again had mild diplopia with no changes in visual acuity. A cranial MRI was done and showed a multilobulated enhancing mass centered in the left supraorbital region measuring 4.4 x 5.4 x 3.3 cm with extension to the left convexity mildly compressing the left frontal lobe, inferior extension to the lateral and extraconal spaces of the left orbit compressing the extraocular muscles (Figure 1). At this time, no intervention was done due to financial constraints and the symptoms did not affect his daily activities.

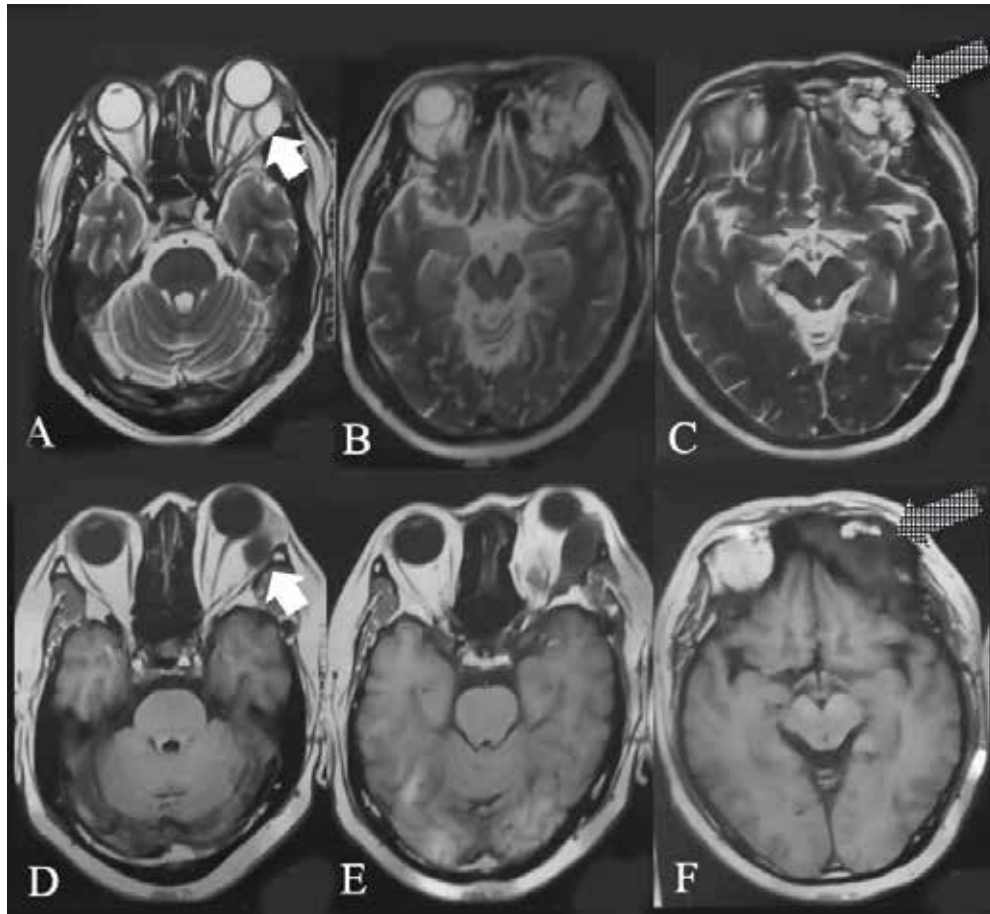


Figure 1 Cranial MRI T2W (A-C) and T1W (D-F) images. White arrows indicate the inferior extent of the lesion compressing the extraocular muscles. Checkered arrows show the Hollow lesion centered over the left supraorbital area.

Almost one year after the initial surgery, the patient decided to consult with another surgeon as the symptoms had become disfiguring and now affected his job in the hospitality service. Examination showed pronounced proptosis with limited movement of the extraocular muscles (Figure 2). Visual acuity remained intact. No other neurologic symptoms were noted. A cranial computed tomography (CT) scan with bone window was then requested as seen in Figure 3 to further define the bony structures near the orbit. CT scan showed a predominantly hypoattenuating expansile, complex mass centered in the left supraorbital region measuring approximately 4.3x3.8x3.4 cm with lytic changes of the left frontal bone, left frontal bar, roof of the orbit and left lateral orbital wall; mass noted to extend to the left frontal and left anterior ethmoid sinus as well as into the left frontal convexity with subsequent mild compression of the frontal lobe.

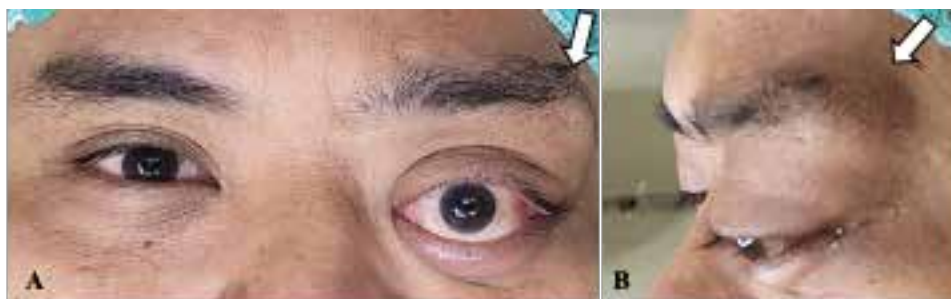

Figure 2. Prior to the second operation, the orbit was notably displaced medially and inferiorly. A bulge can be seen at the lateral to the superior orbital rim (white arrows) as seen in these AP (A) and lateral (B) views.

The patient then underwent a left orbitofrontal craniectomy via a hairline incision carried from the zygoma to the contralateral medial eyebrow. Scalp flap was reflected downward, followed by the periosteum that remained intact after the previous surgery. Dissection was continued until the lesion in the frontal bone was encountered. The affected frontal bone was found to be brittle and friable and was subsequently resected until normal cortical bone was encountered. Curettage of the intraosseous contents until all jelly-like material (Figure 4) was removed was done. The posterior cortex of the frontal bone and affected orbital roof was also resected until normal cortical bone was

again encountered. Reconstruction of the affected areas was done by using a piece of titanium mesh measuring about 5 cm in diameter. This was reshaped in a way that it would create a new orbital roof as well as cover the frontal craniectomy defect to keep the orbital cavity contents from going into the intracranial space. Histopathology was read as a benign bone tumor consistent with myxoma of the bone and showed loosely arranged bland appearing spindle cells in a myxoid background with no significant mitotic activity. The patient was discharged after an unremarkable hospital course and remain asymptomatic on the 3-month follow up seen in Figure 5.

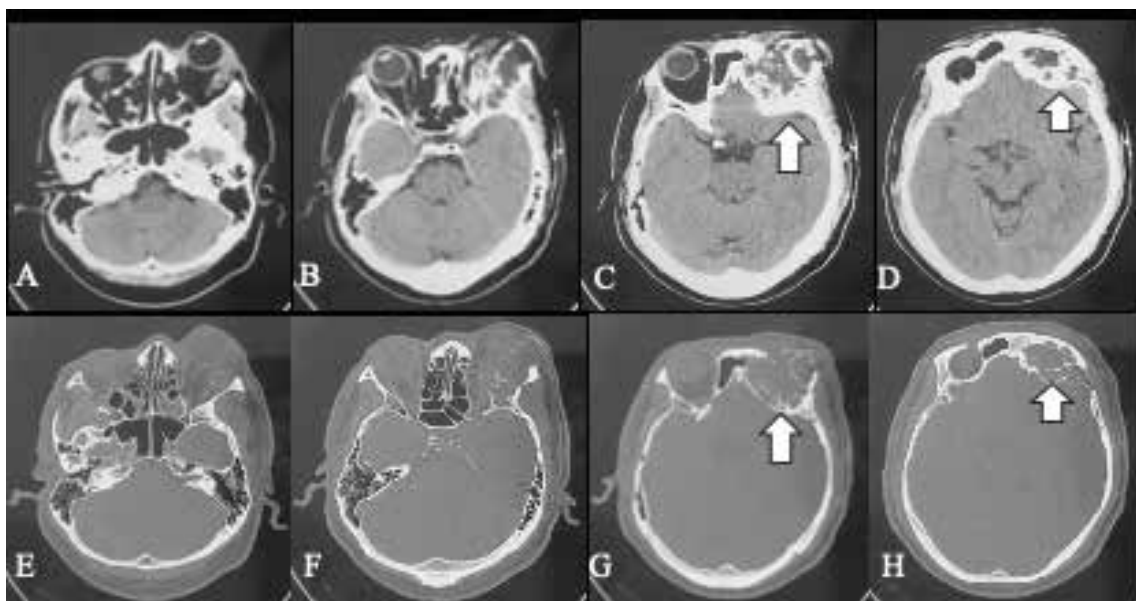


Figure 3. Cranial CT scan (A-D) with bone window (F-H) showing the expansile, complex mass (white arrows) centered on the left supraorbital region extending into the frontal and ethmoid sinuses

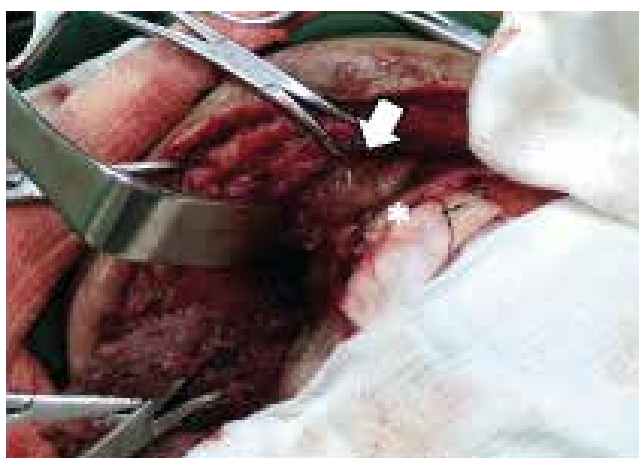

Figure 4. Intraoperatively, the affected frontal bone (*) just above the superior orbital rim was brittle and contained jelly-like material (white arrow) when removed.

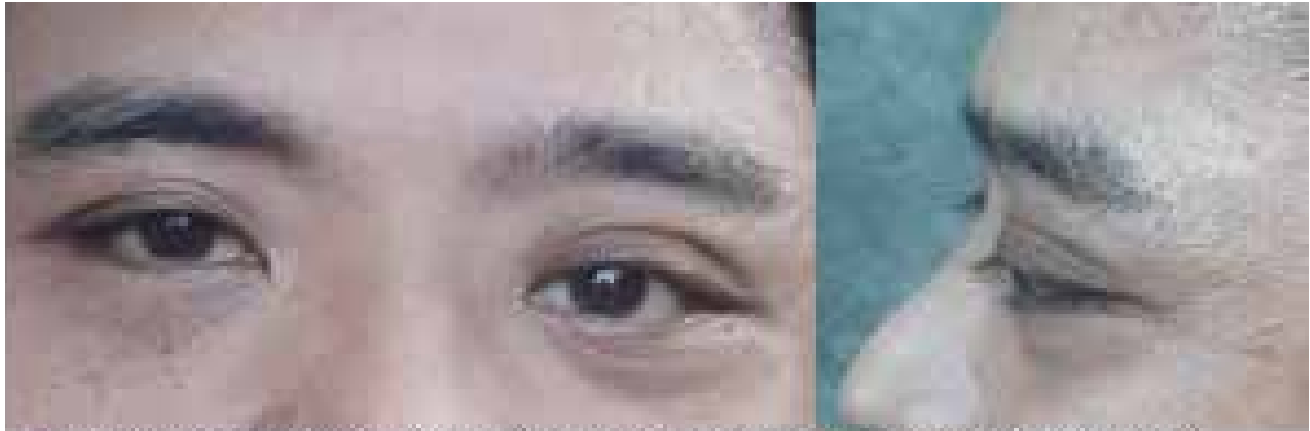

Figure 5. Three months post surgery with reconstruction of the craniectomy defect and orbital rim

DISCUSSION

Myxomas are rare benign tumors of mesenchymal origin, that usually arise from small tissues, most commonly, the heart. These rare tumors are most prevalent in the third and fourth decade with no gender predilection.^{1,3} When these tumors appear in the bones of the head and neck, they usually occur in the mandible, usually from the dental elements of the jaw (odontogenic myxoma).^{2,3} Cases of intraosseous calvarial myxomas are extremely uncommon.

These tumors usually have indolent growth patterns and are only diagnosed once they attain a size big enough to cause symptoms, in our case, proptosis. Many of these tumors progressively enlarge without causing pain. Reports have been made of myxomas causing blindness, otologic symptoms, and neurologic symptoms, indicating that they may cause symptoms from mass effects depending on their location.^{6,7}

Imaging studies play a large role in the diagnosis of these tumors. Myxomas usually appear as multinodular, well-circumscribed expansile lesions with irregular margins and associated destruction/erosion of adjacent bony structures. On CT scan, myxomas appear as hypo- or iso-dense lesions with varying degrees of bone destruction. On MRI, the tumors appear hypointense on T1-weighted images, while hyperintense on T2-weighted images.^{1,3,7-9}

There are no pathognomonic clinical presentations or imaging findings for myxomas but physical examination and imaging, in addition to a high index of suspicion are key to diagnosis. Definitive diagnosis is solely based on histopathologic analysis. Histologically, these tumors appear as spindle to stellate cells with pyknotic nuclei in a myxoid stroma.⁶ Immunohistochemistry may play a role in diagnosis, particularly positivity for vimentin

as well as negativity for S100.^{2,7,8} Differential diagnosis would include benign tumors like meningiomas with myxoid components, schwannomas, skeletal tumors like Langerhan's cell histiocytosis, as well as malignant tumors like sarcomas. Immunohistochemical stains aid in differentiating myxomas from these tumors.^{1,3,4,7}

A multidisciplinary treatment approach is ideal for myxomas. Treatment involves complete resection of the tumor though some reports advocate for wide local excision with safety margins for both primary and recurrent cases.³ Plastic surgery should ideally be involved to achieve the best aesthetic outcome for the patients. Neurosurgery, ophthalmology, and otolaryngology are the commonly involved teams that work together to achieve complete resection of these tumors when they occur in the head and neck region. There are still no guidelines for adjuvant treatment but a few cases advocate for radiotherapy as salvage treatment for unresectable tumors.^{4,8} Close and long-term follow-up should be done because of the high rate of recurrence of these tumors as seen with our case, recurring within 3-months of the first operation. It is important to emphasize to patients strict adherence to regular follow-up to prevent any disfiguring changes.

CONCLUSION

Intraosseous myxomas of the head and neck are still very uncommon lesions. The presented case demonstrates challenges of diagnosis and treatment of such cases. Reconstruction, especially in low-income countries, should be done in a way that maximizes available resources for the patient while ensuring that best outcomes are achieved. Continuous follow-up is recommended because these tumors have high rates of recurrence.

REFERENCES

1. Wei X, Chang T, Shen H. Radiologic features of primary intracranial myxomas from the skull base: 14 Case reports and literature review. *World Neurosurg.* 2019 Jun;126:e77-e83. Available from: <https://doi.org/10.1016/j.surneu.2007.09.015>.
2. Ali MJ, Saha D, Vemuganti GK, Naik MN. Extragathic sino-orbital myxoma: An extremely rare tumor at an even rarer site. *Ophthalmic Plast Reconstr Surg.* 2014 Nov-Dec;30(6):e157-9. Available from: <https://doi.org/10.1097/iop.0000000000000002>.
3. Weisbrod L, Smith K, Camarata P, Alvarado A, Andrews B. Orbital myxoma: A case report. *Surg Neurol Int.* 2020 Mar 13;11:43. Available from: https://doi.org/10.25259/sni_323_2019.
4. Young R, Laing B, Best B, Harrison GL, Zwagerman N. Endoscopic endonasal resection of a primary intraosseous clival myxoma: Illustrative case. *J Neurosurg Case Lessons.* 2022 Oct 31;4(18):CASE22334. Available from: <https://doi.org/10.3171/case22334>.
5. Zhang L, Zhang M, Zhang J, Luo L, Xu Z, Li G, et al. Myxoma of the cranial base. *Surg Neurol.* 2007;68 Suppl 2:S22-8. Available from: <https://doi.org/10.1016/j.surneu.2007.09.015>.
6. Hunchaisri N. Myxoma of the nasal cavity and paranasal sinuses: Report of a case. *J Med Assoc Thai.* 2002 Jan;85(1):120-4.
7. Bhandari V, Phatak S, Kulkarni D, Kawatra M. Primary occipital myxoma: A rare case report. *J Pediatr Neurosci.* 2013;8(2):129. Available from: <https://doi.org/10.4103/1817-1745.117844>.
8. Howser LA, Ye MJ, Boham S, Fan R, Nelson RF. Pediatric intraosseous cranial myxoma: A case report and review of literature. *Clin Case Rep.* 2021 Oct 15;9(10):e04973. Available from: <https://doi.org/10.1002/ccr3.4973>.
9. Osterdock RJ, Greene S, Mascott CR, Amedee R, Crawford BE. Primary myxoma of the temporal bone in a 17-year-old boy: Case report. *Neurosurgery.* 2001 Apr;48(4):945-7; discussion 947-8. Available from: <https://doi.org/10.3171/case22334>.

Conflict of interest: Author declares no conflict of interest.

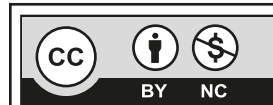Funding disclosure: Nil

Authors' contribution:

Alma Corazon T de la Cruz; concept, case management, manuscript writing

Michael N Sabalza; case management, manuscript writing

All the authors have approved the final version of the article and agree to be accountable for all aspects of the work.



This is an Open Access article distributed under the terms of the Creative Commons Attribution-Non Commercial 2.0 Generic License.