

POST COVID-19 VACCINE GUILLAIN BARRE SYNDROME

Soban Khan¹, Maryam Khalil¹, Zaid Waqar¹, Sajid Khan¹, Zakir Jan¹

¹Department of Neurology, Shaheed Zulfiqar Ali Bhutto Medical University/ PIMS, Pakistan

Correspondence Author: Zaid Waqar Department of Neurology, Shaheed Zulfiqar Ali Bhutto Medical University/ PIMS, Pakistan **Email:** chikky789@gmail.com

Date of submission: May 16, 2022 **Date of revision:** October 08, 2022 **Date of acceptance:** December 02, 2022

ABSTRACT

The Guillain Barre Syndrome (GBS) is an acute immune-mediated progressive polyneuropathy having an acute monophasic illness leading to paralysis. The clinical features are progressive ascending symmetrical muscle weakness that may lead to respiratory failure. Diagnosis is based upon clinical presentation and is supported by a lumbar puncture with CSF analysis demonstrating albumin-cytological dissociation, and electrophysiological studies. Our patient presented to us with progressive ascending paralysis after receiving COVID 19 vaccine.

Key Words: COVID-19, Vaccine, Guillain Barre syndrome, GBS, COVID-19 Vaccine, AIDP, Moderna, mRNA vaccine

INTRODUCTION

The Guillain Barre Syndrome (GBS) is an acute immune mediated progressive polyneuropathy having an acute monophasic illness leading to paralysis. The clinical features are progressive ascending muscle weakness that may lead to respiratory failure, that may necessitate ventilatory support. Other clinical features include facial nerve palsies, oropharyngeal weakness, oculomotor weakness, decreased or absent deep tendon reflexes, paresthesias in the hands and feet, backache and dysautonomia.¹ Proposed mechanism is that an immune response evoked by an infection which leads to the cross reaction with peripheral nerve component because of a molecular mimicry. Diagnosis is based upon clinical presentation and is supported by a lumbar puncture with CSF and electrophysiological studies.² Since the first case of SARS-CoV-2 infection reported in Wuhan, China in December 2019, global emergency caused the urgent need to manufacture the vaccine. A Number of vaccines were approved by FDA including mRNA vaccines viral protein vaccines and adenoviral vector vaccines. These vaccines were instrumental in reducing the mortality from, COVID 19. GBS is one of the neurological complications that can happen with both SARS-CoV-2 infection and vaccination.³ Though the incidence of neurological complications is much higher with COVID-19 than with the vaccines.⁴ A number of cases have been reported world-wide with GB syndrome developing following COVID-19 vaccines but the awareness regarding the neurological side effects among health care professionals remains limited.⁵ We report this case because to date the literature review shows no case of post COVID-19 vaccine GB syndrome has been reported from Pakistan in any of the indexed journals.

CASE PRESENTATION

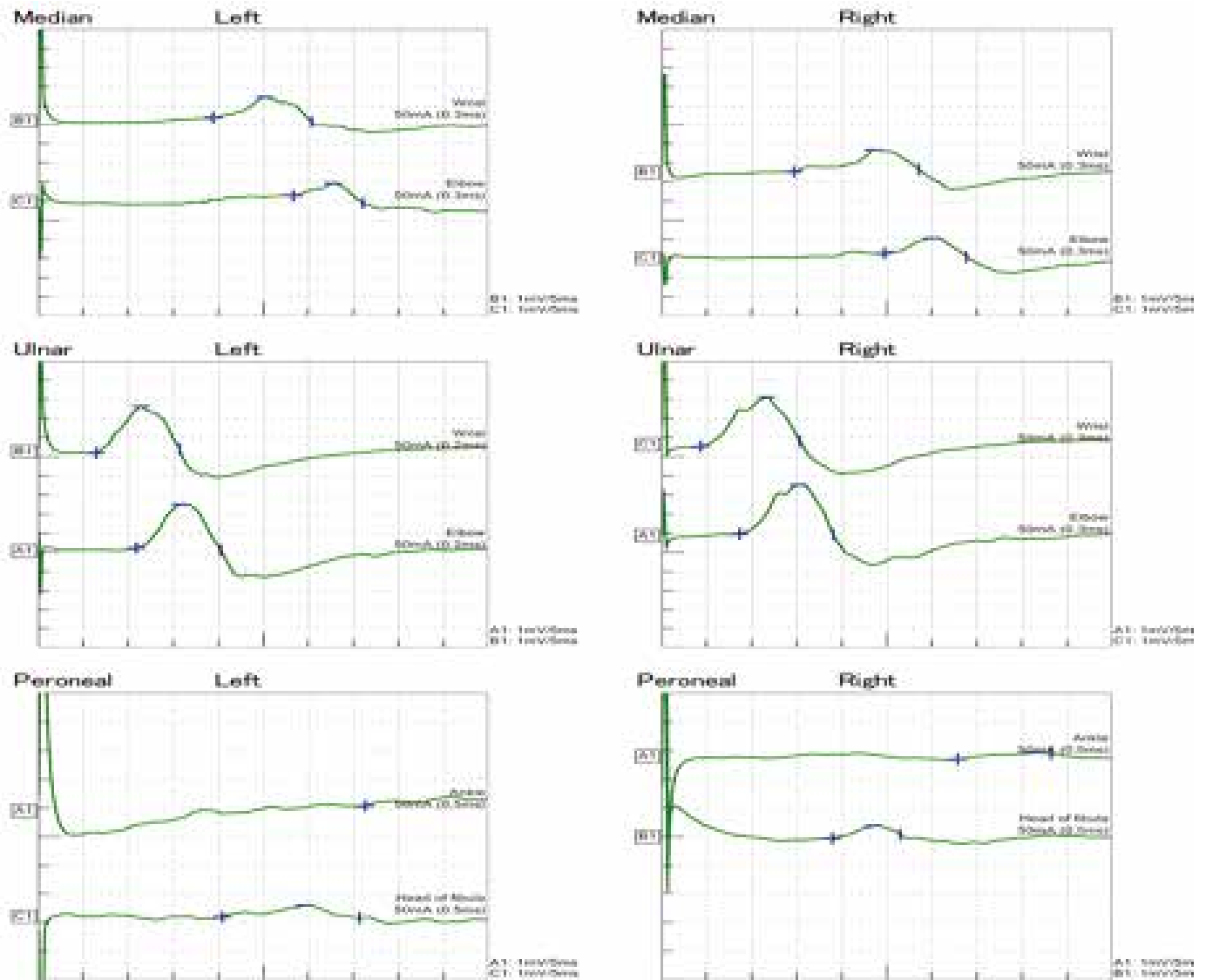
A 28-years-old male, non-smoker, with no known co-morbidities presented to us in the emergency department of Shaheed Zulfiqar Ali Bhutto Medical University/ PIMS, Pakistan complaining of progressive bilateral lower limb weakness for the past six days. He previously had an excellent functional status and denied any history of recent trauma, fever, upper respiratory or gastrointestinal tract illness. There was no weight loss, night sweats or change in bowel habits. He had received first dose of COVID-19 vaccine (Moderna) six days prior to his presentation.

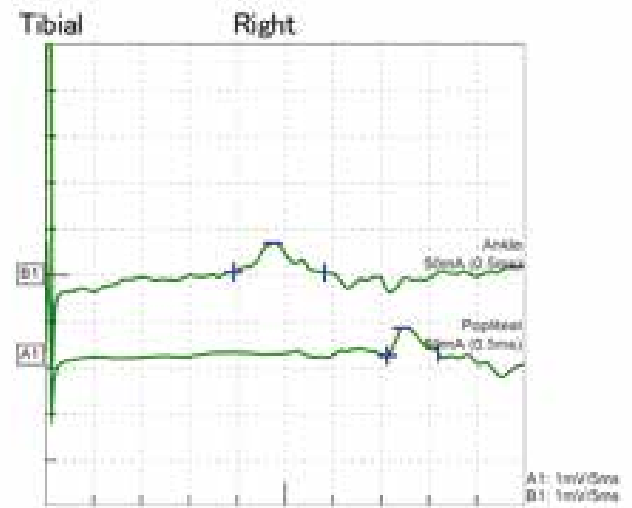
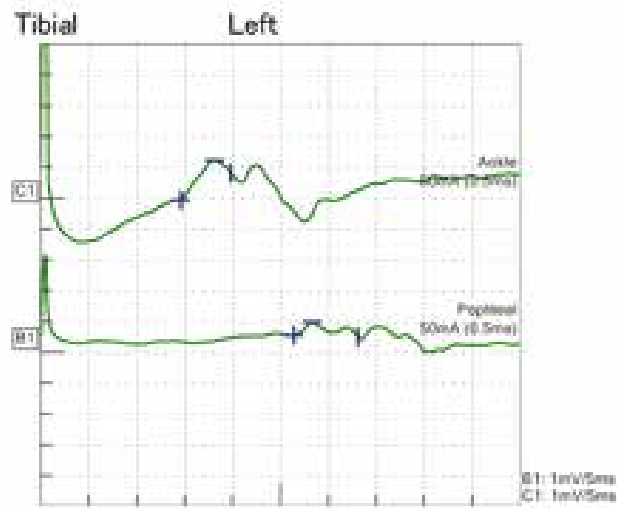
On physical examination, the patient was hemodynamically stable, afebrile, having no signs of respiratory distress. Neurological examination showed Glasgow Coma Scale (GCS) of 15/15, pupils were bilateral equal and reactive, cranial nerves and extra-ocular movements were intact. Bulbar weakness was absent. Motor strength according to Medical Research Council Grade was 3/5 proximally, +3/5 distally in upper limbs and 2/5 proximally and 1/5 distally in lower limbs. The patient was not able to walk and maintaining sitting posture on his own. Deep tendon reflexes were globally absent, and planters were bilateral equivocal. Pin prick and joint position sensations were intact. There was no nystagmus or dysidiadochokinesia.

Complete blood count showed mild leukocytosis of $11.4 \times 10^3 /\mu\text{L}$ (reference range $4-10 \times 10^3 /\mu\text{L}$) with neutrophilic predominance, and normal hemoglobin and platelet count. His serum electrolyte including serum potassium, renal, hepatic and coagulation profile and muscle enzymes were normal. C-reactive

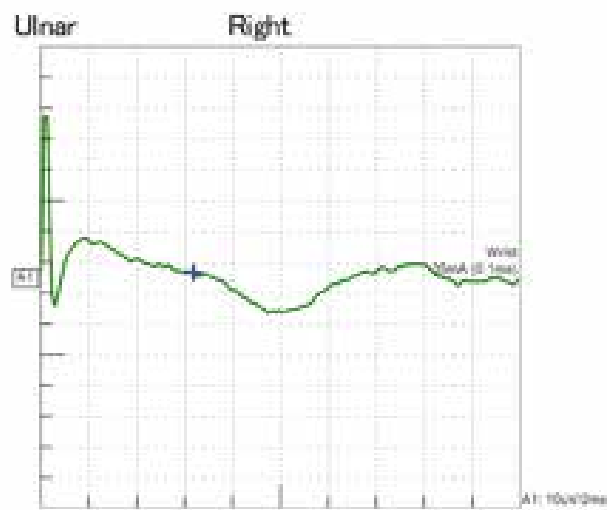
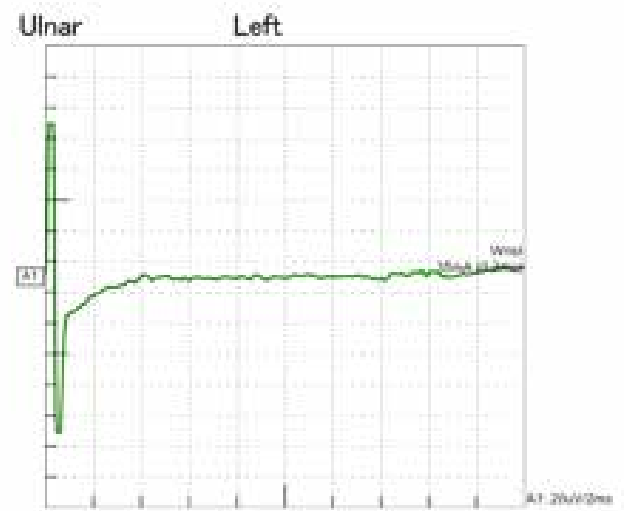
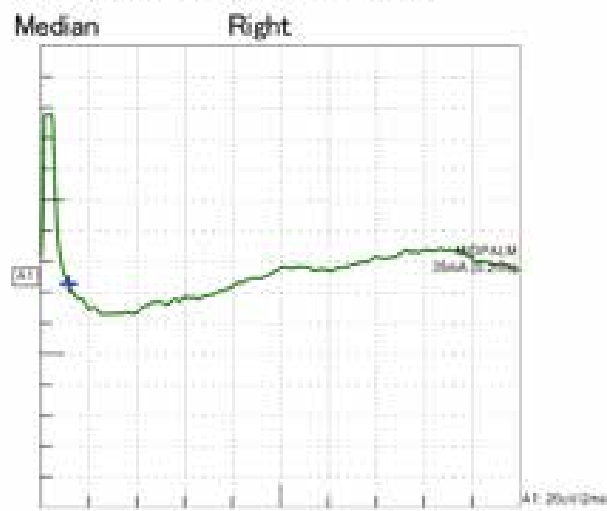
protein was negative. COVID-19 PCR from a nasopharyngeal swab was negative. Cerebrospinal fluid examination to look for albumin cytological dissociation was in plan but patient refused to give consent despite counseling. Nerve Conduction Study (NCS) showed low amplitude with prolong latency and low conduction velocity in right and left median and ulnar motor nerves. No response was shown in right sensory median and right and left sensory ulnar and peroneal motor nerve.

Low amplitude, prolong latency and reduced conduction velocity in right and left tibial motor nerve. Right median and ulnar nerves F waves showed no response. Right sural nerve was not recordable. The graphs are presented in Figure 1. The electrophysiological findings were consistent with Acute Inflammatory Demyelinating Polyneuropathy (AIDP) variant of GB syndrome.





Sensory Nerve Conduction Study



F-wave

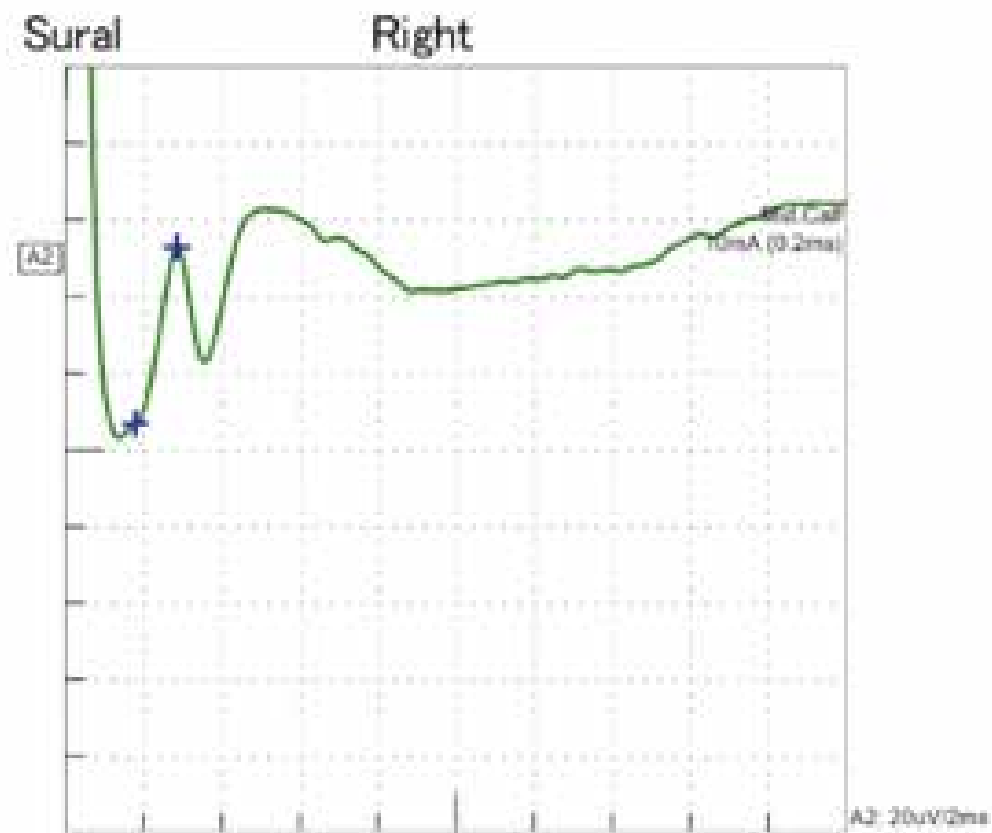
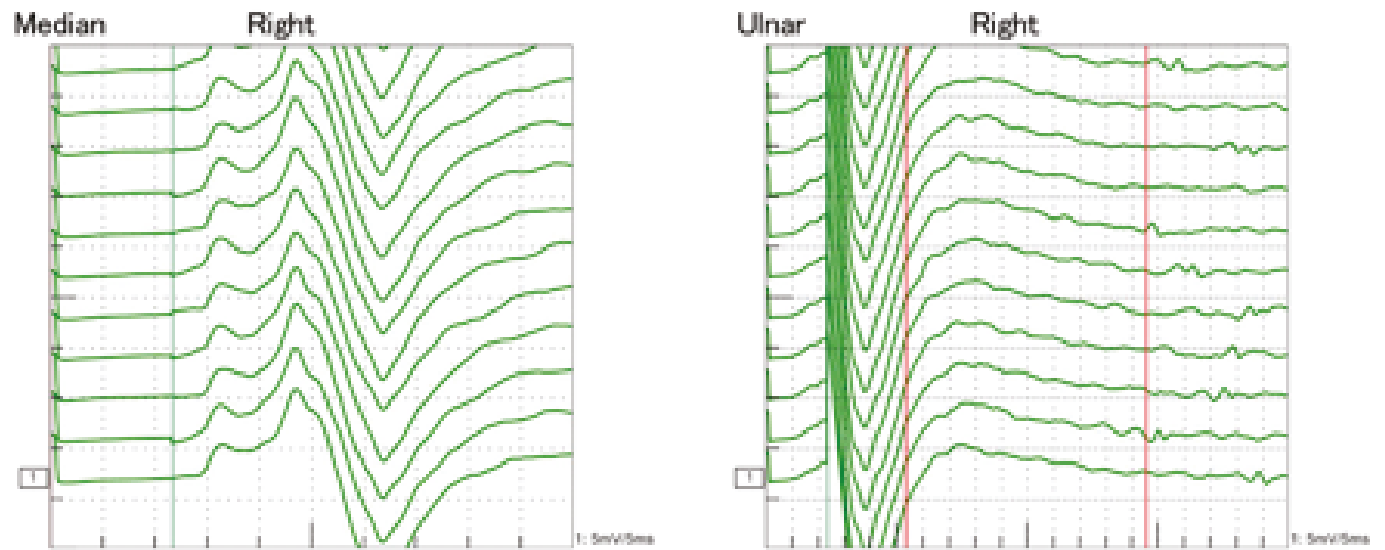


Figure 1: Graphs of detailed nerve conduction studies of the patient

Based on the Brighton criteria for case definition of Guillain-Barre syndrome, diagnosis was established. The patient showed no signs of respiratory distress and autonomic dysfunction throughout his stay at hospital. Treatment options Intravenous Immunoglobulins (IVIGs) versus Plasma Exchange (PE) along with risks and benefits and cost effectiveness were explained to patient in detail. He opted for Plasma Exchange and underwent 5 sessions of PE on alternate days. He showed signs of improvement in ambulation and overall function. He tolerated Plasma Exchange sessions without any adverse side effects. As he remained stable and responded well to the treatment, he was discharged and referred to an outpatient rehabilitation facility two weeks after admission. In rehabilitation facility he received extensive physical and occupational therapy. After four weeks, he followed up in Neurology OPD, where physical examination showed the marked recovery of muscle power (grade +4/5 in upper limbs and 4/5 in the lower limbs).

DISCUSSION

We report this case to spread awareness about the possible association of GBS with COVID-19 vaccination. The underlying mechanisms for GBS with COVID-19 vaccines and other vaccines at this point is postulated to be molecular mimicry that results in cross reactivity of immune response to neuronal and myelin elements of peripheral nervous system.⁶ There is growing evidence that cross reactivity of infective agent epitopes and peripheral nerve gangliosides may play a role. Several other antecedent events including surgery, cancer, pregnancy, autoimmune disease, and vaccinations (swine flu vaccine of 1976) has been linked to GBS.⁷

Review of available data for GBS after COVID vaccines showed that incidence of GBS after mRNA vaccines is 1.3 per 100000 person-years which is almost similar to general population data however the Janssen vaccine which wasn't used in Pakistan has higher incidence of GBS than others that is 32.4 per 100000 person-years.⁴ A review of vaccine associated GBS published in 2008 before COVID-19 pandemic reported that most cases were actually temporal associations and not causations and that the strongest association was with swine flu vaccine.⁸

First reported case of GBS in Malta was temporally related to Vaxzevria vaccination.⁹ Other two cases of GBS been reported related to ChAdOx1-S/nCoV-19 vaccine in England and India.¹⁰ Another case was reported in Qatar secondary to Pfizer vaccination. As of October 2021, 2163 cases of GBS and its variants (including 46 cases of Miller-Fisher syndrome and 13 cases of Bickerstaff's encephalitis) have been reported after vaccination with the ChAdOx1 nCoV-19 (AstraZeneca) or the two messenger RNA-based COVID-19 vaccines.¹¹

CONCLUSION

Before establishing the conclusion, further studies are required. Vaccinations leading to reduction in morbidity and mortality outweigh the risk of reported adverse events. However, before stating or eliminating a causal relationship between COVID-19 vaccine and GBS, large scale studies are required.

REFERENCES

1. Ropper AH. The Guillain-Barre syndrome. *N Engl J Med.* 1992;326(17):1130.
2. Fokke C, van den Berg B, Drenthen J, Walgaard C, van Doorn PA, Jacobs BC. Diagnosis of Guillain-Barré syndrome and validation of Brighton criteria. *Brain.* 2014;137(Pt 1):33-43.
3. Min YG, Ju W, Ha YE, Ban JJ, Lee SA, Sung JJ, et al. Sensory Guillain-Barre syndrome following the ChAdOx1 nCov-19 vaccine: Report of two cases and review of literature. *J Neuroimmunol.* 2021;359:577691.
4. Hanson KE, Goddard K, Lewis N, Fireman B, Myers TR, Bakshi N, et al. Incidence of Guillain-Barré Syndrome After COVID-19 Vaccination in the Vaccine Safety Datalink. *JAMA Netw Open.* 2022;5(4):e228879.
5. Germano F, Bellucci M, Grisanti S, Beronio A, Grazzini M, Coco E, et al. COVID-19 vaccine-related Guillain-Barré syndrome in the Liguria region of Italy: A multicenter case series. *J Neurol Sci.* 2022;440:120330.
6. Anjum Z, Iyer C, Naz S, Jaiswal V, Nepal G, Laguio-Vila M, et al. Guillain-Barré syndrome after mRNA-1273 (Moderna) COVID-19 vaccination: A case report. *Clin Case Rep.* 2022;10(4):e05733.
7. Lasky T, Terracciano GJ, Magder L, Koski CL, Ballesteros M, Nash D, et al. The Guillain-Barré syndrome and the 1992-1993 and 1993-1994 influenza vaccines. *The New England journal of medicine.* 1998;339(25):1797-802.
8. Haber P, Sejvar J, Mikaeloff Y, DeStefano F. Vaccines and Guillain-Barré syndrome. *Drug Saf.* 2009;32(4):309-23.
9. McKean N, Chircop C. Guillain-Barré syndrome after COVID-19 vaccination. *BMJ Case Rep.* 2021;14(7).
10. Maramattom BV, Krishnan P, Paul R, Padmanabhan S, Cherukudal Vishnu Nampoothiri S, Syed AA, et al. Guillain-Barré Syndrome following ChAdOx1-S/nCoV-19 Vaccine. *Ann Neurol.* 2021;90(2):312-4.
11. Kim JE, Park J, Min YG, Hong YH, Song TJ. Associations of Guillain-Barré syndrome with coronavirus disease 2019 vaccination: Disproportionality analysis using the World Health Organization pharmacovigilance database. *J Peripher Nerv Syst.* 2022 Sep;27(3):206-214

Conflict of interest: Author declares no conflict of interest.

Funding disclosure: Nil

Author's contribution:

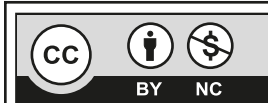
Soban Khan; data collection, data analysis, manuscript writing, manuscript review

Mariam Khalil; data collection, data analysis, manuscript writing, manuscript review

Zaid Waqar; data collection, data analysis, manuscript writing, manuscript review

Sajid Khan; manuscript writing, manuscript review

Zakir Jan; manuscript writing, manuscript review



This is an Open Access article distributed under the terms of the Creative Commons Attribution-Non Commercial 2.0 Generic License.