



9-2022

Experience with Anti Nmda Receptor Antibody Encephalitis in A Tertiary Care Hospital in Pakistan

Haris Majid Rajput

Pakistan Institute of Medical Sciences Islamabad Pakistan

Zaid Waqar

Pakistan Institute Of Medical Sciences Islamabad

Muhammad Hassan

Pakistan Institute of Medical Sciences, Islamabad

Neelma Naz Khattak

Pakistan Institute Of Medical Sciences Islamabad

Umair Hassan

Pakistan Institute Of Medical Sciences Islamabad

See next page for additional authors

Follow this and additional works at: <https://ecommons.aku.edu/pjns>



Part of the [Neurology Commons](#)

Recommended Citation

Rajput, Haris Majid; Waqar, Zaid; Hassan, Muhammad; Khattak, Neelma Naz; Hassan, Umair; Athar, Iqra; and Badshah, Mazhar Badshah (2022) "Experience with Anti Nmda Receptor Antibody Encephalitis in A Tertiary Care Hospital in Pakistan," *Pakistan Journal of Neurological Sciences (PJNS)*: Vol. 17: Iss. 3, Article 8.

Available at: <https://ecommons.aku.edu/pjns/vol17/iss3/8>

Experience with Anti Nmda Receptor Antibody Encephalitis in A Tertiary Care Hospital in Pakistan

Authors

Haris Majid Rajput, Zaid Waqar, Muhammad Hassan, Neelma Naz Khattak, Umair Hassan, Iqra Athar, and Mazhar Badshah Badshah

EXPERIENCE WITH ANTI NMDA RECEPTOR ANTIBODY ENCEPHALITIS IN A TERTIARY CARE HOSPITAL IN PAKISTAN

Haris Majid Rajput¹, Zaid Waqar¹, Muhammad Hassan¹, Neelma Naz Khattak¹, Umair Hassan¹, Iqra Athar², Mazhar Badshah¹

¹.Pakistan Institute of Medical Sciences, Islamabad, Pakistan

².Pakistan Air Force Hospital, Islamabad, Pakistan

Corresponding author: Haris Majid Rajput Pakistan Institute of Medical Sciences, Islamabad, Pakistan **Email:** harismajid@gmail.com

Date of submission: July 29, 2022 **Date of revision:** September 20, 2022 **Date of acceptance:** September 20, 2022

ABSTRACT

Background and objective:

Anti NMDA receptor (Anti-NMDAR) antibody encephalitis is an increasingly recognized form of auto immune encephalitis. The objective of this study was to determine the demographic, clinical and laboratory factors associated with this syndrome.

Methods:

All cases presenting to neurology, Pakistan institute of medical sciences, Islamabad, from June 2017 till January 2020 were reviewed retrospectively. Patients fulfilling the diagnostic criteria for Anti NMDA receptor (Anti-NMDAR) antibody encephalitis were included. All patients were evaluated with cerebrospinal fluid (CSF) routine examination, MRI brain, autoimmune encephalitis profile and for presence of oligoclonal bands (OCB) in CSF. Statistical analysis was done using SPSS version 23.0.

Results:

A total of seven patients were diagnosed as having Anti-NMDAR antibody encephalitis. Five patients were female and two were male. Four patients had some type of psychiatric disturbances upon presentation of these behavioral abnormalities and irritability were found in all four. Orofacial abnormal movements were found in four patients while one patient had myoclonic seizures.

Conclusion:

Anti-NMDAR receptor encephalitis is a common cause of encephalitis associated with neurological and psychiatric symptoms. Delay in diagnosis can occur due to non-specific symptoms and signs present in early stages of illness, this can lead to long term neurological disability.

Key Words: Anti-NMDAR encephalitis, Immunosuppressive therapy, Plasmapheresis, IVIG

INTRODUCTION

Anti NMDA receptor antibody encephalitis was first reported in 2007 by Dalmau and colleagues in association with teratoma of ovaries.¹ However, later it was found to occur without a paraneoplastic association, and in males too. Anti NMDAR encephalitis is the second most common of autoimmune encephalitis comprising of about four percent of all causes of encephalitis.² Anti NMDAR encephalitis develops due to formation of IgG antibodies against the NR1 subunit of NMDA receptor. Symptoms of encephalitis develop through a prodrome of flu like illness with myalgias, body aches, with or without low

grade fever, followed by psychiatric features that include behavioral abnormalities and irritability that are more common in children, to aggression hallucinations and frank psychosis which is more often seen among adult patients.³ At this stage many patients are diagnosed with psychiatric and or substance abuse disorders because of scarcity of neurological signs and symptoms. This is followed by development of neurological dysfunction causing a variety of signs and symptoms ranging from seizures and catatonia to coma and movement disorders.

Autonomic dysfunction is also a well-documented

feature of anti NMDAR encephalitis, causing abnormalities in blood pressure and cardiac rate and rhythm. Autonomic dysfunction due to its cardiovascular side effects is major cause of mortality in such patients. Up to 59% of anti NMDAR encephalitis can be associated with malignancies.⁴ Malignancies are uncommon in patients below the age of 18; other associations include viral infections like EBV, Herpes encephalitis and mycoplasma infection. Diagnosis is confirmed with the help of auto-antibodies tested in CSF and serum and treatment is with immune therapy. With early recognition and treatment, patients' outcomes are improved. The objective of this study was to determine the demographic, clinical and laboratory factors associated with this syndrome.

METHODS

Study design: Retrospective cross-sectional observational study

Place and duration of study: All cases presenting to neurology, Pakistan institute of medical sciences, Islamabad, from June 2017 till January 2020 were reviewed.

Sample size: A total number of seven patients were included in the study.

Sampling technique: Non-probability consecutive sampling.

Data collection: Patients fulfilling the diagnostic criteria for Anti NMDA receptor (Anti-NMDAR) antibody encephalitis were included.⁵ All patients were evaluated with cerebrospinal fluid (CSF) routine examination, MRI brain, autoimmune encephalitis profile and for presence of oligoclonal bands (OCB) in CSF. Relevant differential diagnoses were excluded as indicated. Case data was obtained for a total of seven patients.

Statistical analysis: The data were analyzed using SPSS version 23.0.

RESULTS

A total of seven patients were diagnosed as having Anti-NMDAR antibody encephalitis (Table 1).^{6,7}

Demography:

Patient population in this case series ranged from 14-30 years of age with the mean age being 19 years. Five patients were female and two were male.

Clinical characteristics:

Four out of seven patients included had a prodrome with flu like symptoms before the start of neuropsychiatric features. Four patients had some type of psychiatric disturbances upon presentation of these behavioral abnormalities and irritability were found in all four, while one patient each had hallucinations and paranoia (Figure 1). Autonomic dysfunction with urinary incontinence was present in two patients. All patients had altered level of consciousness at some point in their disease course, and six out of seven patients had seizures. Orofacial abnormal movements were found in four patients while one patient had myoclonic seizures.

Lab workup and Neuroimaging:

All patients underwent work up including CSF analysis, neuroimaging and screening for malignancy. CSF showed pleocytosis in five cases and CSF for Anti-NMDAR antibody was positive in six cases while the seventh patient had a clinical diagnosis and supported by response to treatment. MRI Brain in all cases showed either non-significant T2 changes or a normal MRI. Malignancy screen done via tumor markers and imaging survey was negative in all cases. EEG showed nonspecific slowing of background rhythm and encephalopathic changes in six patients

Treatment

All the patients were treated with IV methylprednisolone pulse therapy followed by plasma exchanges, with four patients requiring additional therapy i.e. oral steroids/azathioprine. Six patients had good recovery while one had moderate response to treatment. One patient received cyclophosphamide therapy while none received rituximab. Follow up showed no relapse in any case.

Table 1: Clinical data of anti NMDAR antibody encephalitis patients

	Case 1	Case 2	Case 3	Case 4	Case 5	Case 6	Case 7
Age and gender	14/ F	16/F	22/M	16/M	21/F	14/ F	30/F
Prodrome	No	No	Yes	Yes	Yes	No	Yes
Psychiatric Features	Yes	Yes	No	No	Yes	Yes	No
Altered consciousness	Yes	Yes	Yes	Yes	Yes	Yes	Yes
Seizures	No	Yes	Yes	Yes	Yes	Yes	Yes
Abnormal Movements	stereotypies , Lip bite	No	Myoclonus	No	Orofacial /Hands	Orofacial /Hands	Orofacial /Hands
Autonomic Dysfunction	Urinary incontinence	No	No	No	Urinary incontinence	No	No
CSF R/E findings	Pleocytosis	Normal	Pleocytosis	Pleocytosis	Pleocytosis	Normal	Pleocytosis
CSF autoantibodies	Present	Present	Present	Present	Present	Present	Absent
EEG changes	Present	Present	Present	Present	Present	Absent	Present
Malignancy	No	No	No	No	No	No	No
Treatment	IVMP 5days,Plasma exchange , Cyclophosphamide	IVMP 5 days, Plasma exchange , oral steroids	IVMP 7 days	IVMP 5 days, Plasma exchange , oralsteroids, Azathioprine	IVMP 5 days, Plasma exchange , oral steroids	IVMP 5 days, Plasma exchange , oral steroids	IVMP 5 days, Plasma exchange
Response	Good	Good	Good	Good	Good	Good	Fair

IVMP: Intravenous methylprednisolone

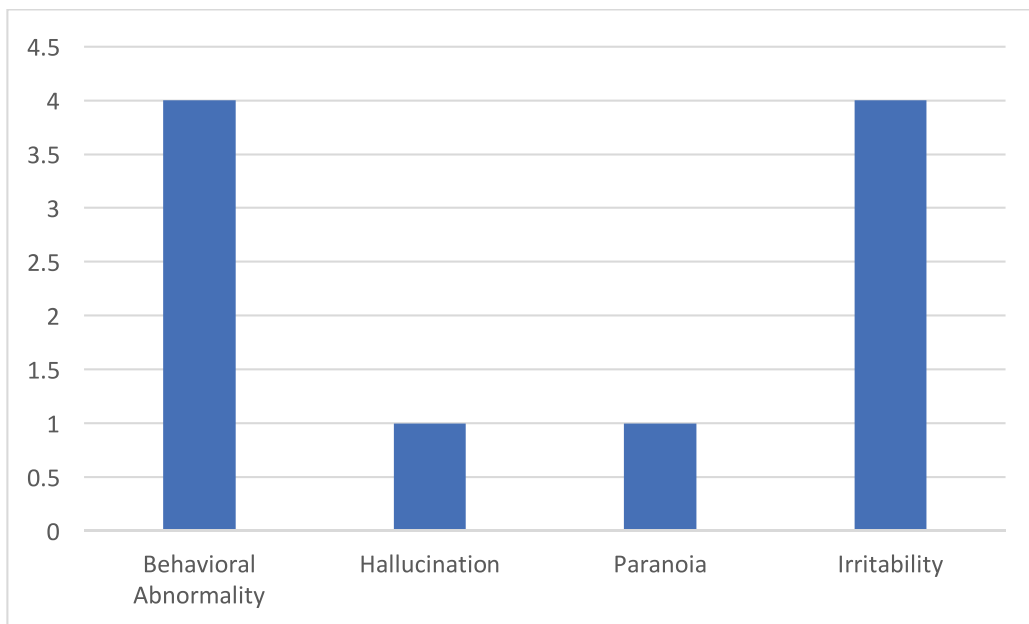


Figure 1: Psychiatric features in anti NMDA receptor antibody encephalitis patients

DISCUSSION

Anti NMDAR encephalitis was originally reported in association with ovarian teratomas, however it has been found to occur malignancies as well.⁸ The published literature has shown that about 80% of the cases occur in females with median age of 21.⁸ In this case series five out of seven patients were females that is 71% and the mean age was 19. Anti NMDAR encephalitis is the second most common cause of autoimmune encephalitis after acute disseminated encephalomyelitis. Its symptoms progress through a prodrome of flu like illness to psychiatric and behavioral abnormalities, which were present in four of our patients.

Majority patients develop generalized seizures during the course of illness and at this point they come under consult of a neurologist and work up is started. Abnormal movements are common in patients, mostly they involve face and arms. These movements when present are an important red flag signs in patient with behavioural and psychiatric symptoms and consideration should be given to diagnosis of autoimmune encephalitis in such cases. Abnormal movements were found in four of our patients.

CSF routine analysis can be normal or can show mild pleocytosis, other findings include unpaired oligoclonal in CSF. Confirmation of diagnosis is done with CSF autoantibody for NMDAR these can be also be detected in serum but sensitivity in serum is low than CSF.⁹ An extensive search for underlying tumour is warranted in all cases of anti NMDAR encephalitis with imaging of chest and abdomen/pelvis and tumour markers.

Treatment of anti NMDAR encephalitis is with immunotherapy with IV high dose steroids being the first line of treatment, these are often followed by IVIG/Plasma exchanges as steroids by themselves alone have poor response. Decision between IVIG and Plasma exchange depends on availability, comorbid conditions and presence or absence of autonomic dysfunction. Most cases respond well to first line immunotherapy with up to 97% having a good response at two years follow up.⁸

The first case of anti NMDAR encephalitis from Pakistan was reported in 2015.⁹ So far three case series of anti NMDAR encephalitis patients have been published from Pakistan from the cities of Rawalpindi, Islamabad and Peshawar.¹⁰⁻¹² A comparison of demographics of our cases with those three publications is given in table 2.

Table 2: Comparison of demographic features of autoimmune encephalitis publications from Pakistan

	Anwar SO et al ¹⁰	Sheikh S et al ¹¹	Haq AU et al ¹²	Current study
Number of patients	11	8	17	7
Female to male ratio	5:6	7:1	12:5	5:2
Mean age	31.18	15	Not mentioned	19

CONCLUSION

A total of seven patients were diagnosed as having Anti-NMDAR antibody encephalitis. Five out of the seven patients were female and two were male. Four

patients had some type of psychiatric disturbances upon presentation of these behavioral abnormalities and irritability were found in all four. A good response to treatment was noted in six out of seven patients.

REFERENCES

1. Dalmau J, Tüzün E, Wu HY, Masjuan J, Rossi JE, et al. Paraneoplastic anti-N-methyl-D-aspartate receptor encephalitis associated with ovarian teratoma. *Ann Neurol.* 2007;61(1):25-36.
2. Dalmau J, Graus F. Antibody-Mediated Encephalitis. *N Engl J Med.* 2018;378:840-51
3. Dalmau J, Armangué T, Planagumà J, Radosevic M, Mannara F, Leypoldt F, et al. An update on anti-NMDA receptor encephalitis for neurologists and psychiatrists: mechanisms and models. *Lancet Neurol.* 2019;18(11):1045-57.
4. Dalmau J, Gleichman AJ, Hughes EG, Rossi JE, Peng X, Lai M, et al. Anti-NMDA-receptor encephalitis: case series and analysis of the effects of antibodies. *Lancet Neurol* 2008;7:1091-8.
5. Graus F, Titulaer MJ, Balu R, Benseler S, Bien CG, Cellucci T, et al. A clinical approach to diagnosis of autoimmune encephalitis. *Lancet Neurol.* 2016;15(4):391-404.
6. Zubair UB, Majid H. Anti-NMDA Receptor Encephalitis in a Young Girl with Altered Behaviour and Abnormal Movements. *J Coll Physicians Surg Pak.* 2018;28(8):643-644
7. Waqar Z, Rajput HM, Hassan M, Athar I, Khattak NN, Badshah M. Anti-NMDA Receptor Encephalitis. *Pak J Neurol Sci.* 2021;16(2):23-6.
8. Titulaer MJ, McCracken L, Gabilondo I, Armangué T, Glaser C, Iizuka T, et al. Treatment and prognostic factors for long-term outcome in patients with anti-NMDA receptor encephalitis: an observational cohort study. *Lancet Neurol.* 2013;12(2):157-65.
9. Memon RK, Siddiqui M, Khan R. Encephalopathy with behavioural and psychiatric features – first antibody proven case of anti-NMDA receptor encephalitis from Pakistan. *Pak J Neurol Sci.* 2015; 10:27-9
10. Anwar SO, Liaqat J, Alamgir W. Characteristics and outcomes in patients with anti N-Methyl-D-Aspartate receptor auto-immune encephalitis. *Pak Armed Forces Med J.* 2018;1(2):202-6.
11. Sheikh S, Ahmad A, Ahmed TA. Anti NMDA receptor antibody encephalitis in Pakistan: Clinicopathological features and treatment outcomes. *J Pak Med Assoc.* 2019;69(12):1910-1914.
12. Haq AU, Nabi D, Alam M, Ullah SA. The Spectrum of Movement Disorders in Anti-N-Methyl-D-Aspartate Receptor (NMDAR) Encephalitis Both in Children and Adults: An Experience From a Single Tertiary Care Center. *Cureus.* 2021;13(12):e20376.

Conflict of interest: Author declares no conflict of interest.

Funding disclosure: Nil

Authors' contribution:

Haris Majid Rajput; concept, data collection, data analysis, manuscript writing, manuscript review

Zaid Waqar; data collection, data analysis, manuscript writing, manuscript review

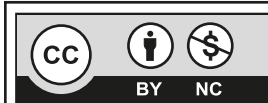
Muhammad Hassan; concept, data analysis, manuscript review

Neelma Naz Khattak; data collection, data analysis, manuscript writing

Umair Hassan; data collection, data analysis, manuscript writing

Iqra Athar; data analysis, manuscript writing

Mazhar Badshah; concept, manuscript review



This is an Open Access article distributed under the terms of the Creative Commons Attribution-Non Commercial 2.0 Generic License.